

# Tracheostomy in Patients With COVID-19: A Single-center Experience

KAZUFUMI OBATA<sup>1</sup>, RYO MIYATA<sup>1</sup>, KEISUKE YAMAMOTO<sup>1</sup>, NAOFUMI BYN-YA<sup>2</sup>,  
TAKEHIKO KASAI<sup>2</sup>, HIROYUKI INOUE<sup>2</sup>, EICHI NARIMATSU<sup>2</sup> and KENICHI TAKANO<sup>1</sup>

<sup>1</sup>Department of Otolaryngology, Sapporo Medical University School of Medicine, Sapporo, Japan

<sup>2</sup>Department of Emergency Medicine, Sapporo Medical University School of Medicine, Sapporo, Japan

**Abstract.** *Background/Aim:* Tracheostomy performed on patients with Coronavirus disease 2019 (COVID-19) may lead to the infection of operators and medical staff. To date, there are no established methods of infection control. The aim of this study was to provide helpful and useful information regarding tracheostomy during the COVID-19 pandemic. *Patients and Methods:* We performed a retrospective analysis on 12 patients with severe COVID-19 who were intubated and underwent tracheostomy in our hospital. *Results:* Percutaneous tracheostomy was performed in eight cases, and open tracheostomy was performed in four cases. Open tracheostomy in the operating room was performed under a negative pressure closed-space system using a surgical drape to prevent aerosolization. *Conclusion:* Our experience suggests that bedside percutaneous tracheostomy may be a useful option in patients with COVID-19. In cases where percutaneous tracheostomy is anticipated to be difficult, open tracheostomy using a negative pressure closure may be useful in preventing aerosolization and reducing the risk of infection of healthcare workers.

Pneumonia in patients with severe Coronavirus disease 2019 (COVID-19) is likely to require long-term tracheal intubation management and eventually, tracheostomy. Tracheostomy in patients with COVID-19 with prolonged intubation can shorten the duration of mechanical ventilation, reduce the requirement for intravenous sedation, improve hygiene and comfort, as well as enhance resource utilization (1). However,

This article is freely accessible online.

*Correspondence to:* Kenichi Takano, Department of Otolaryngology, Sapporo Medical University School of Medicine, S1W16, Chuo-ku, Sapporo 060-8556, Japan. Tel: +81 116889655, Fax: +81 116155405, e-mail: kent@sapmed.ac.jp

*Key Words:* COVID-19, tracheostomy, infection, aerosolization.

since many viruses are present on the airway mucosal surface of patients with COVID-19, when aerosols are generated during tracheostomy, the virus can float in the air for up to three hours, exposing healthcare workers to the virus (2, 3). Therefore, tracheostomy for patients with COVID-19 should be performed according to the institutional standards for the procedure, patient selection, and operating time (4). In addition, a safe operation in a short time by an experienced operator is required while paying careful attention to the prevention of aerosolization (5). Tracheostomy includes percutaneous and open procedures. There is no evidence regarding which method is superior in preventing aerosolization, and the procedure should be selected in consideration of the available medical resources and patient's background (4). Open tracheostomy in the operating room is often preferable, particularly, in cases where tracheostomy is anticipated to be difficult, such as in obese patients, swelling of the thyroid gland, history of cervical surgery, and history of head and neck cancer. As an aerosolization prevention method, safe operations have been reported by covering the patient with a transparent cover during open tracheostomy to create a negative pressure enclosed space (6). In this paper, we report our experience of patients with COVID-19 who underwent tracheostomy at our facility, and describe a case of open tracheostomy using a negative pressure closed-space system with a surgical drape.

## Patients and methods

*Patients.* We conducted an institutional analysis of all patients admitted to Sapporo Medical University Hospital from March 1, 2020 to June 30, 2020 who had COVID-19 confirmed through a polymerase chain reaction (PCR) assay, developed severe respiratory failure requiring mechanical ventilation and underwent tracheostomy. The Sapporo Medical University institutional review board approved this study.

*Procedure.* At our institution, tracheostomy is indicated for patients with COVID-19 who are expected to have long-term intubation and have been confirmed PCR-negative, twice consecutively. Tracheostomy was performed while wearing full personal protective equipment (PPE);

Table I. Patients with COVID-19 who underwent tracheotomy.

| Age | Gender | Intubation days | Procedure              | Indication for tracheostomy | BMI  | Complications               |
|-----|--------|-----------------|------------------------|-----------------------------|------|-----------------------------|
| 61  | M      | 14              | Bed side, Percutaneous | Sputum obstruction          | 25.7 | HT, DM, pAf                 |
| 59  | M      | 11              | Bed side, Percutaneous | Unable to wean              | 24.1 | Emphysema                   |
| 63  | M      | 16              | Bed side, open         | Sputum obstruction          | 22.7 | Chronic hepatitis, DM, COPD |
| 56  | F      | 8               | Bed side, open         | Unable to wean              | 32.8 | Asthma, Breast cancer       |
| 68  | M      | 15              | Bed side, Percutaneous | Unable to wean              | 22.0 | COPD DM                     |
| 63  | F      | 18              | operating room, open   | Unable to wean              | 22.7 | Asthma COPD DM HL AP        |
| 63  | F      | 11              | Bed side, Percutaneous | Unable to wean              | 31.1 | DM                          |
| 52  | M      | 6               | Bed side, Percutaneous | Unable to wean              | 23.4 | DM ALD                      |
| 69  | M      | 9               | Bed side, Percutaneous | Unable to wean              | 24.3 | HT HL                       |
| 68  | M      | 28              | Bed side, Percutaneous | Unable to wean              | 25.7 | HT DM                       |
| 73  | M      | 18              | Bed side, Percutaneous | Unable to wean              | 32.7 | HT HL                       |
| 41  | M      | 30              | operating room, open   | Unable to wean              | 36.0 | DM HL                       |

BMI: Body mass index, HT: hypertension, DM: diabetes, pAf: paroxysmal atrial fibrillation, COPD: chronic obstructive pulmonary disease, HL: hyperlipidemia, AP: angina pectoris.

filtering facepiece particles 2 (FFP2) mask, face shield with or without goggles for eye protection, impermeable long-sleeved gown and surgical cap with minimal skin exposure). Anesthesia was administered with deep sedation and full neuromuscular blockade (Rocuronium, 1.2 mg/kg) to prevent the cough reflex. In addition, the tracheal tube was not released into the air.

Tracheostomy was performed by the percutaneous method in the intensive care unit at the bedside of patients with COVID-19, considering the risk of viral spread associated with patient migration. For percutaneous tracheostomy, we inserted the intubation tube deeper than usual, inserted a disposable bronchoscope into the trachea with the cuff of the intubation tube inflated, punctured the trachea using a percutaneous tracheostomy kit (Neo Perc™, Medtronic plc, Ireland) with the light of the bronchoscope, and inserted a trachea cannula with a cuff.

In cases where safe tracheostomy was anticipated to be difficult, such as in patients with a short neck, obesity, and thyroid enlargement, open tracheostomy was performed using a negative pressure closed space to prevent aerosolization.

## Results

The baseline characteristics of patients with COVID-19 (9 males and 3 females) who underwent tracheostomy are shown in Table I. The median age was 63 years (range=41-73 years; average: 61.3 years; Table I). All patients who underwent tracheostomy had two consecutive negative COVID-19 PCR findings. The main indications for tracheostomy were weaning of respiratory withdrawal and removal of sputum. All patients were intubated, and the intubation period was 6-30 days (with an average of 15.3 days). Eight patients underwent bedside percutaneous tracheostomy, and four patients underwent open tracheostomy. In cases requiring an open operation, percutaneous tracheostomy was anticipated to be difficult. In

the treatment of patients with COVID-19 including tracheostomy, no healthcare worker or inpatient got infected in our hospital.

As a representative case, we present the details of a 41-year-old male, complicated with diabetes and hyperlipidemia. His weight and height were 114 kg and 178 cm, respectively (body mass index: 35.9 kg/m<sup>2</sup>). In addition, his neck was very short (Figure 1). Thirty days after intubation, extracorporeal membrane oxygenation and anticoagulants were used. Open tracheostomy was performed in a negative pressure operating room to prevent aerosolization. Prior to surgery, the surgeons, anesthesiologists, and nurses in the operating room were consulted and a careful simulation was performed. The patient was transported in and out of the operating room with a minimum number of medical personnel equipped with standard PPE with spatial and temporal separation. The surgeons wore full PPE, and tracheostomy was performed using standard procedures until the trachea was opened. Hemostasis was carefully managed. A suction tube was fixed near the surgical field so that smoke produced by electrocoagulation would be discharged automatically. At the time of tracheal fenestration, we tried to prevent droplet formation and aerosolization by using a drape over the body of the patient (Figure 2A, B). We used a sterile drape to cover the da Vinci® surgical system (Intuitive Surgical, CA, USA). Before applying the drape, we prepared the surgical instruments and a cannula in the surgical field. We made armholes in the drape, and tracheal fenestration was performed in a closed space. The tracheal cartilage was incised in an inverted U shape and fixed to the skin. After sufficient hemostasis was performed, a cannula was placed in the trachea. The surgery time was 35 min.

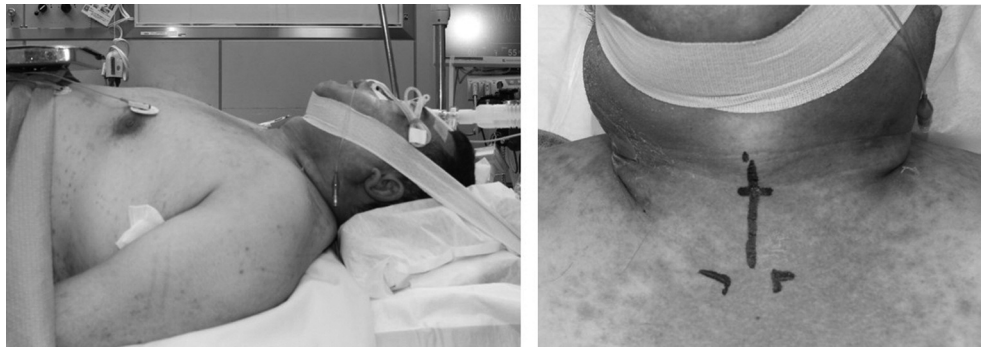

Figure 1. Obese patient (114 kg, body mass index: 35.9 kg/m<sup>2</sup>) with a short neck. The shoulder pillow was inserted as usual, and the chin was pulled with an elastic tape to extend the neck. The cricoid cartilage was touched from the body surface. A vertical incision was made from the thyroid cartilage immediately above the clavicle.

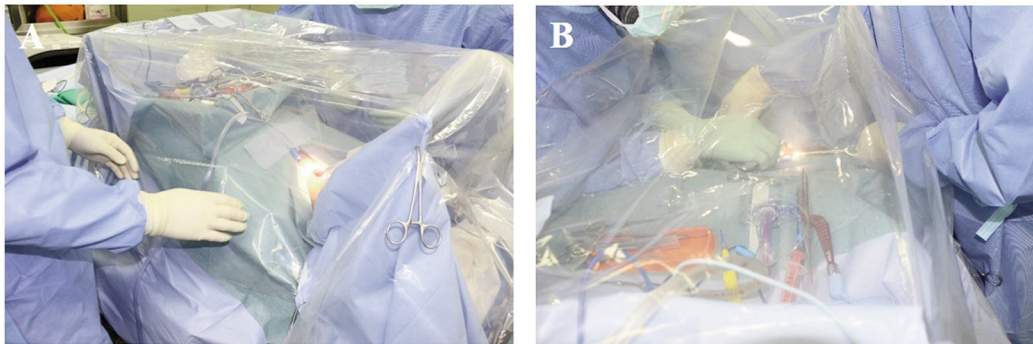


Figure 2. Tracheostomy using a closed system. A. After preparing the tracheal fenestration, negative pressure closure was initiated. In order to secure a working space for the anesthetist, the head side of the patient was lengthened to prevent splashing of droplets during extubation. B. The circuit, tracheal cannula, and instruments were loaded into the enclosure prior to the procedure.

## Discussion

For long-term intubation of patients with severe COVID-19, tracheostomy is crucial for improving the patient's prognosis, respiratory withdrawal, and securing medical resources (1). However, to reduce the risk of infection of medical staff due to aerosolization, it is necessary to establish a safe tracheostomy method.

Regarding the timing of tracheostomy, it has been reported that it should be done at least 14 days after intubation, considering the high mortality rate of patients with COVID-19 (4). Similar to the general tracheostomy timing for intubated patients, we considered that performing tracheostomy approximately 7-14 days after intubation can improve the treatment prognosis of patients with COVID-19. Recent guidance suggests that tracheostomy may be delayed until at least day 10 of mechanical ventilation, only in patients who show signs of clinical improvement (7).

Considering the risk of viral spread associated with patient migration, we performed bedside percutaneous tracheostomy in cases with low bleeding risk. It has been reported that percutaneous tracheostomy is effective in terms of safety and infection control for healthcare workers (8). In our experience, percutaneous tracheostomy could be performed without any major trouble.

Open tracheostomy was performed in cases anticipated to be difficult for percutaneous tracheostomy. In these cases, it was possible to perform surgery safely by using a negative pressure closed-space system with a surgical drape for the da Vinci<sup>®</sup> surgery system to prevent aerosolization and exposure. The drape for the negative pressure closed space has been previously used as a medical resource in our facility. It was a readily available resource in our facility and we could easily use it without preparing new items. Bertroche *et al.* (9) reported that drape application is fast (5 min) and does not require any special procedure. In this case,

it was possible to create a negative pressure closed space in a short time, and the tracheostomy was completed in 35 min, indicating it is a simple and time-saving method.

However, there are several challenges with this method. Although this surgical drape for the da Vinci® system is transparent and the operative field can usually be confirmed without any problem, the surgical light can sometimes be reflected on the cover, making it difficult to see. Therefore, it takes time and effort to change the position of the light and correct the reflection to confirm the operative field. When the operators' arms are inserted into the drape, if the distance between the arms is too close, it is difficult to perform the surgical procedure in the negative pressure closed space. Therefore, a simulation is needed to determine the appropriate position for the armholes. It is also necessary to create a space on the drape near the patient's head to prevent aerosolization when the anesthesiologist extubates. We believe it is important for the corresponding anesthesiologist and operating room staff to carry out simulations.

We have had no incidences of in-hospital infection, and we consider that both percutaneous and open tracheostomy in patients with COVID-19 can be performed safely by employing appropriate measures. We think that percutaneous tracheostomy may be recommended for patients with COVID-19, especially in those for whom tracheostomy would not be difficult (such as our representative case), because it reduces the risk of infection transmission from the patient and reduces the number of medical personnel involved in the procedure. However, in high-risk patients for tracheostomy, open tracheostomy using a negative pressure closed-space system may be a better option. Recent guidance has emphasized the reduction of aerosol generation and exposure risk by using closed systems, appropriate or enhanced PPE, powered air-purifying respirators, eye protection, fluid-repellent disposable surgical gowns, and gloves (7, 10).

This report is from a single center with a small number of cases. Therefore, more discussion is necessary regarding the indication and policies of tracheostomy for patients with COVID-19 by studying a large number of patients in future studies.

## Conclusion

In patients with COVID-19, bedside percutaneous tracheostomy was performed for low-risk patients while open tracheostomy for high-risk patients. These procedures ensure the safety of both patients and healthcare workers. Open tracheostomy under a negative pressure closed-space system using a surgical drape is an effective method that permits safe and fast surgery and prevents aerosolization and exposure to the virus.

## Conflicts of Interest

The Authors declare that they have no conflicts of interest relevant to this study.

## Authors' Contributions

Kazufumi Obata: Designed the study and contributed towards data analysis, interpretation of the results, and writing the first draft. Ryo Miyata, Keisuke Yamamoto, Naofumi Bun-ya and Hiroyuki Inoue performed tracheostomies. Takehiko Kasai: Performed tracheostomy and contributed towards data analysis. Eichi Narimatsu: Reviewed the literature and had final approval of the paper. Kenichi Takano: Provided critical revision of the article and final approval of the paper.

## References

- 1 Prabhakaran K, Malcom R, Choi J, Chudner A, Moscatello A, Panzica P, Latifi R and Rhee P: Open tracheostomy for COVID-19-positive patients: a method to minimize aerosolization and reduce risk of exposure. *J Trauma Acute Care Surg* 89: 265-271, 2020. PMID: 32404630. DOI: 10.1097/TA.0000000000002780
- 2 Zou L, Ruan F, Huang M, Liang L, Huang H, Hong Z, Yu J, Kang M, Song Y, Xia J, Guo Q, Song T, He J, Yen HL, Peiris M and Wu J: SARS-CoV-2 Viral load in upper respiratory specimens of infected patients. *N Engl J Med* 382: 1177-79, 2020. PMID: 32074444. DOI: 10.1056/NEJMc2001737
- 3 Kligerman MP, Vukkadala N, Tsang RKY, Sunwoo JB, Holsinger FC, Chan JYK, Damrose EJ, Kearney A and Starmer HM: Managing head and neck cancer patients with tracheostomy or laryngectomy during the COVID-19 pandemic. *Head Neck* 42: 1209-1213, 2020. PMID: 32298035. DOI: 10.1002/hed.26171
- 4 Takhar A, Walker A, Tricklebank S, Wyncoll D, Hart N, Jacob T, Arora A, Skilbeck C, Simo R and Surda P: Recommendation of a practical guideline for safe tracheostomy during the COVID-19 pandemic. *Eur Arch Otorhinolaryngol* 277: 2173-2184, 2020. PMID: 32314050. DOI: 10.1007/s00405-020-05993-x
- 5 Givi B, Schiff BA, Chinn SB, Clayburgh D, Iyer NG, Jalisi S, Moore MG, Nathan CA, Orloff LA, O'Neill JP, Parker N, Zender C, Morris LGT and Davies L: Safety recommendations for evaluation and surgery of the head and neck during the COVID-19 pandemic. *JAMA Otolaryngol Head Neck Surg* 146: 579-584, 2020. PMID: 32232423. DOI: 10.1001/jamaoto.2020.0780
- 6 Foster P, Cheung T, Craft P, Baran K, Kryskow M, Knowles R, Toia A, Galvez C, Bowling A and DiSiena M: Novel approach to reduce transmission of COVID-19 during tracheostomy. *J Am Coll Surg* 230: 1102-1104, 2020. PMID: 32283268. DOI: 10.1016/j.jamcollsurg.2020.04.014
- 7 McGrath BA, Brenner MJ, Warrillow SJ, Pandian V, Arora A, Cameron TS, Añon JM, Hernández Martínez G, Truog RD, Block SD, Lui GCY, McDonald C, Rassekh CH, Atkins J, Qiang L, Vergez S, Dulguerov P, Zenk J, Antonelli M, Pelosi P, Walsh BK, Ward E, Shang Y, Gasparini S, Donati A, Singer M, Openshaw PJM, Tolley N, Markel H and Feller-Kopman DJ: Tracheostomy in the COVID-19 era: global and multidisciplinary guidance. *Lancet Respir Med* 8: 717-725, 2020. PMID: 32422180. DOI: 10.1016/S2213-2600(20)30230-7



- 8 Angel L, Kon ZN, Chang SH, Rafeq S, Palasamudram Shekar S, Mitzman B, Amoroso N, Goldenberg R, Sureau K, Smith DE and Cerfolio RJ: Novel percutaneous tracheostomy for critically ill patients with COVID-19. *Ann Thorac Surg* *110*: 1006-1011, 2020. PMID: 32339508. DOI: 10.1016/j.athoracsur.2020.04.010
- 9 Bertroche JT, Pipkorn P, Zolkind P, Buchman CA and Zevallos JP: Negative-pressure aerosol cover for COVID-19 tracheostomy. *JAMA Otolaryngol Head Neck Surg* *146*: 672-674, 2020. PMID: 32343299. DOI: 10.1001/jamaoto.2020.1081
- 10 Pandian V, Morris LL, Brodsky MB, Lynch J, Walsh B, Rushton C, Phillips J, Rahman A, DeRose T, Lambe L, Lami L, Wu SPM, Garza FP, Maiani S, Zavali A, Okusanya KA, Palmieri PA, McGrath BA, Pelosi P, Sole ML, Davidson P, and Brenner MJ: Critical care guidance for tracheostomy care during the COVID-19 pandemic: a global, multidisciplinary approach. *Am J Crit Care* e1-e12, 2020. PMID: 32929453. DOI: 10.4037/ajcc2020561

*Received September 14, 2020*

*Revised October 8, 2020*

*Accepted October 9, 2020*